American Journal of Infection Control 45 (2017) e26-e33

Contents lists available at ScienceDirect

American Journal of Infection Control

journal homepage: www.ajicjournal.org

Major Article

Longitudinal assessment of reprocessing effectiveness for colonoscopes and gastroscopes: Results of visual inspections, biochemical markers, and microbial cultures

Cori L. Ofstead MSPH [a,*], Harry P. Wetzler MD, MSPH [a], Otis L. Heymann BA [a], Ellen A. Johnson BAS [a], John E. Eiland MS, RN [a], Michael J. Shaw MD [b]

[a] Ofstead & Associates, Inc, Saint Paul, MN
[b] Division of Gastroenterology, Department of Medicine, University of Minnesota Medical School, Minneapolis, MN

Key Words:
Endoscope
Adenosine triphosphate
Epidemiology

Background: Flexible endoscopes are currently reused following cleaning and high-level disinfection. Contamination has been found on endoscopes, and infections have been linked to gastrointestinal, respiratory, and urologic endoscopes.

Methods: This longitudinal study involved visual inspections with a borescope, microbial cultures, and biochemical tests for protein and adenosine triphosphate to identify endoscopes in need of further cleaning or maintenance. Three assessments were conducted over a 7-month period. Control group endoscopes reprocessed using customary practices were compared with intervention group endoscopes subjected to more rigorous reprocessing.

Results: At final assessment, all endoscopes (N = 20) had visible irregularities. Researchers observed fluid (95%), discoloration, and debris in channels. Of 12 (60%) endoscopes with microbial growth, 4 had no growth until after 48 hours. There were no significant differences in culture results by study group, assessment period, or endoscope type. Similar proportions of control and intervention endoscopes (~20%) exceeded postcleaning biochemical test benchmarks. Adenosine triphosphate levels were higher for gastroscopes than colonoscopes ($P = .014$). Eighty-five percent of endoscopes required repair due to findings.

Conclusions: More rigorous reprocessing was not consistently effective. Seven-day incubation allowed identification of slow-growing microbes. These findings bolster the need for routine visual inspection and cleaning verification tests recommended in new reprocessing guidelines.

Guidelines for reprocessing flexible endoscopes currently permit reuse following cleaning and high-level disinfection (HLD), which theoretically eliminates all bioburden except small numbers of bacterial spores.[1-5] However, organic residues often remain after manual cleaning[6-10] and endoscope contamination has persisted in institutions with documented adherence to reprocessing guidelines.[9,11-13] The presence of residual material after cleaning reduces HLD effectiveness,[14] and researchers have recovered nonspore-forming microbes on 8%-64% of patient-ready endoscopes following HLD.[9,11-13,15-17]

Although inadequate reprocessing is commonly found during endoscopy-associated outbreak investigations,[1,5,18] infections have also occurred when guidelines were followed.[12,19] Outbreaks involving duodenoscopes have illuminated challenges specific to cleaning their elevator mechanisms,[12,20,21] but infections have also been linked to endoscopes without elevators, including gastroscopes,[22] colonoscopes,[23] bronchoscopes,[18,24] and urologic endoscopes.[25,26] Studies using advanced microscopy have found that residual protein and biofilm are not completely removed from channels during reprocessing, even with multiple rounds of cleaning.[27,28] In 3 outbreaks, surface damage and biofilm were found when implicated endoscopes were examined by manufacturers.[12,21,29]

* Address correspondence to Cori L. Ofstead, MSPH, Ofstead & Associates, Inc, 400 Selby Ave, Suite V, Blair Arcade W, Saint Paul, MN 55102.
E-mail address: cori@ofsteadinsights.com (C.L. Ofstead).

Supported in part by research grants from 3M Company, Medivators Inc, and HealthMark Industries, who were not involved in designing the study, collecting data, interpreting results, or preparing the manuscript. In accordance with the study protocol, the research site received a new automated endoscope reprocessor and reprocessing materials from Medivators and supplies for conducting adenosine triphosphate tests from 3M Company.

Conflicts of interest: CLO is employed by Ofstead & Associates, Inc, which has received research funding and speaking honoraria related to infection prevention from 3M Company, Medivators, HealthMark Industries, STERIS Corporation, Boston Scientific, and Invendo Medical. HPW, OLH, EAJ, and JEE, are employed by Ofstead & Associates, Inc.

http://dx.doi.org/10.1016/j.ajic.2016.10.017

To identify endoscopes needing additional cleaning or maintenance, new reprocessing guidelines recommend that more emphasis be placed on conducting visual inspections. They recommend using lighted magnification[2-4] and borescopes,[2] which are small cameras for inspecting endoscope channels and ports. New guidelines also recommend routine tests for biochemical markers such as protein, hemoglobin, and adenosine triphosphate (ATP) be conducted to verify cleaning effectiveness.[2,3]

In a previous study, repeated attempts to remove residue on highly contaminated colonoscopes and gastroscopes were not sufficient to meet benchmarks for manually cleaned endoscopes.[9] Most of these endoscopes had been in use for more than 4 years and had been used for more than 2,000 procedures (data on file in possession of the authors). The findings raised the possibility that organic residue and biofilm accumulation could be associated with factors such as endoscope age, procedure volume, and repair history.

This longitudinal study was designed to evaluate the feasibility and utility of visual inspections combined with biochemical tests and microbial cultures to identify endoscopes in need of further cleaning or maintenance. Researchers assessed endoscope surfaces and contamination levels over time and evaluated the influence of more rigorous methods on reprocessing effectiveness.

MATERIALS AND METHODS

Setting

This prospective study was conducted in an ambulatory surgery center where researchers documented adherence to reprocessing guidelines during 10 unannounced audits (1 prestudy and 9 during the study). Researchers had previously conducted reprocessing effectiveness studies[9-11] and received training from clinical educators employed by borescope and biochemical test manufacturers. The Institutional Review Board granted a waiver because the research subjects were flexible endoscopes, no human subjects were involved, and no patient health data were collected.

Study design

Researchers compiled data on endoscope age, procedure volume, and repair history. Endoscopes were visually inspected and assessed for residual contamination at baseline, 2 months, and final assessments in April, June, and October 2015, respectively. Following baseline, researchers evenly distributed endoscopes to control and intervention groups using their serial numbers and data regarding endoscope type, acquisition date, and procedure volume (supplementary Table S1). To maintain similar group sizes and characteristics, additional endoscopes acquired during the study were assigned to groups using the characteristics described above.

Reprocessing methods

The facility's usual reprocessing practices included bedside precleaning, which involved wiping external surfaces and flushing channels with detergent immediately after procedures, followed by leak testing, manual cleaning, and HLD with 2.5% glutaraldehyde in automated endoscope reprocessing (AER) machines (Intercept Bedside Kit, Intercept detergent, Pull-Thru Cleaning Device, Scope Buddy Endoscope Flushing Aid, and DSD 201 AER; Medivators Inc, Minneapolis, MN) in a reprocessing room.

Control group endoscopes were reprocessed in accordance with the protocol described above. For the intervention group, bedside precleaning, leak testing, and manual cleaning were performed as described above before reprocessing in a different AER that performed automated cleaning before HLD with 5% peracetic acid (PA) (Advantage Plus, Medivators Inc). The change to PA was based on evidence that glutaraldehyde can cause protein fixation and PA's ability to remove buildup from glutaraldehyde use.[1] For every intervention endoscope, reprocessing technicians verified the effectiveness of manual cleaning by conducting biochemical tests for ATP on biopsy ports (BPs) and in suction-biopsy channels (SBCs) (CleanTrace ATP Surface and ATP Water; 3M Company, St Paul, MN). Intervention endoscopes were recleaned whenever results exceeded the "clean" benchmark of 200 relative light units (RLUs).[6,30] When ATP levels remained high after recleaning, endoscopes were subjected to 2 AER cycles, with repeat testing after the first cycle.

To aid in drying, both types of AERs performed alcohol flushes (30 mL) and forced-air purges after HLD. The AER air-purge cycle was set for 1 minute at baseline. The cycle time was increased to 6 minutes in both groups after the baseline assessment identified residual fluid in several endoscopes. Following removal from AERs, endoscopes were wiped with lint-free towels and hung vertically in closed, ventilated cabinets.

Visual inspections

At baseline, 2 months, and final assessments, visual inspections were performed on patient-ready endoscopes. External surfaces were photographed using an 8-megapixel digital camera (iSight; Apple Inc, Cupertino, CA) whenever defects, irregularities, or debris were identified. The distal end and the interior of the air–water port, suction port, BP, and SBC were examined using a 3.2 mm borescope with 17× magnification (Flexible Inspection Scope; HealthMark Industries, Fraser, MI). To facilitate longitudinal comparisons and determine whether there were visible surface changes over time, borescope photographs were captured at specific locations inside every endoscope and whenever irregularities were observed. Videos were recorded when there were lengthy segments of abnormalities and when fluid or debris occluded the channel or moved when disturbed by the borescope. Endoscope serial numbers, photograph or video location, and comments about irregularities were documented.

Biochemical tests and microbial cultures

Samples were collected using aseptic technique in a procedure room dedicated for research use. At the final assessment, samples were collected from BPs and SBCs after manual cleaning and again after an AER cycle. First, BPs were sampled for microbial cultures using sterile swabs that were placed immediately in liquid Amies media to support microbial viability (480c ESwabs; COPAN Diagnostics Inc, Murrieta, CA). Then the flush-brush-flush technique[9,10,19] was used with 35 mL sterile water for obtaining SBC effluent that was used for microbial cultures, ATP tests (CleanTrace ATP Water), and protein tests (ProCheck-II; HealthMark Industries). Following the collection of channel effluent, the biopsy port was sampled again with a sterile swab for ATP testing (CleanTrace ATP Surface). The ATP and protein tests were conducted in accordance with manufacturers' instructions, and published benchmarks were used to evaluate results (6.4 μg/mL protein; 200 RLU ATP).[6,30]

Positive and negative controls (a precleaned gastrointestinal endoscope and a sterilized cystoscope, respectively) were tested to verify aseptic technique and validate results. A sterilized cystoscope was used as a negative control because samples could be obtained using methods that were similar to the process for sampling gastrointestinal endoscopes. Results were expected to be negative, and were compared with findings from a precleaned gastrointestinal endoscope to verify that the biochemical tests were functioning properly.

For the final assessment, microbial culture samples were placed in coolers with ice packs and transported to a local commercial microbiology laboratory (Biotest Laboratories, Inc, Brooklyn Park, MN) within 2 hours of sample collection for processing. Samples were filtered through 0.45 μm nitrocellulose filters before being plated and incubated on tryptic soy agar at 30°C-35°C and on blood agar at 28°C-32°C. Plates were checked for growth every 24 hours for 5-7 days. At 5 days, species identification processes were initiated for specimens with substantial growth, whereas those with little or no growth were monitored for 7 days. Speciation was performed using Gram stains, coagulase testing, and matrix-assisted laser desorption ionization-time of flight mass spectroscopy with ribosomal protein analysis. In accordance with Centers for Disease Control and Prevention and Australian guidelines, cultures with potential pathogens or microbial growth ≥10 CFU were considered especially concerning.[5,31]

Researchers and site personnel developed a risk assessment protocol requiring endoscopes that repeatedly failed to meet cleaning benchmarks, had cultures with pathogens or ≥10 CFU, or had concerning visible abnormalities be sent for additional reprocessing or repair. To assist with interpreting visible abnormalities, researchers compared findings with new endoscopes and images in manufacturers' maintenance bulletins.

Statistical analyses

Statistical analyses were conducted using Excel version 2013 (Microsoft Corporation, Santa Rosa, CA) and SPSS Statistics version 21 (IBM-SPSS Inc, Armonk, NY). Analyses included descriptive statistics and measures of central tendency (means and medians). Fisher exact test was used to test differences in proportions for residual contamination testing results by study group, endoscope type, and assessment time. Statistical significance was defined as a P value < 0.05.

RESULTS

Sample size and characteristics

During the 7-month study period, the site used a total of 22 gastrointestinal endoscopes (gastroscope model GIF-HQ190, adult colonoscope model CF-HQ190L [AC], pediatric colonoscope model PCF-H190L [PC]; Olympus America, Center Valley, PA). There were 17 endoscopes in use at baseline, 19 at 2 months, and 20 at final assessment (supplementary Table S1). At baseline, all endoscopes had <2.5 years of use and ≤530 uses. The 2 endoscopes acquired in December 2014 had been used 35 and 40 times, whereas the 15 endoscopes acquired in December 2012 had been used from 384-530 times before study initiation in April 2015. During the study, 5 long-term rental endoscopes were obtained due to decreased efficiency associated with study activities and the absence of endoscopes that were quarantined after baseline testing and required extensive repairs. Mean total use during the study was lower for ACs (39 uses) than gastroscopes (64 uses) or PCs (87 uses), and loaner endoscopes were used a mean of 54 times. All endoscopes in use at each assessment were included in sample collection and analysis. Baseline and 2-month results have been reported previously.[32]

Visual observations

During the final assessment, researchers observed discoloration, scaly deposits, debris, scratches, and dents on external surfaces. Gastroscope insertion tubes were commonly stained yellow or orange and buckling was also observed. Irregularities were often found on distal ends (Fig 1). Borescope examinations revealed numerous irregularities, including discoloration, scratches, and filaments of debris protruding into channels (Fig 2). Researchers observed fluid in 19 of 20 (95%) patient-ready endoscopes, which were stored vertically after reprocessing. Fluid characteristics varied (eg, clear, cloudy, opaque, or shimmery). Analysis of cloudy residual fluid samples detected simethicone, as previously reported.[33]

The appearance of endoscope surfaces changed considerably over time, with additional irregularities visible at final assessment. In control endoscopes, discoloration and debris observed at baseline appeared similar at the 2-month and final assessments, whereas some of the discoloration and debris observed in the intervention group at baseline diminished over time (Fig 3).

Before study initiation, 9 of 17 endoscopes had been repaired. After the baseline assessment, 2 endoscopes were sent for repair due to staining and filaments of debris hanging into the channel. After the 2-month assessment, 4 other endoscopes were sent for repair due to substantial visible irregularities (n = 3) or a failed leak test (n = 1). At the final assessment, all endoscopes had visible irregularities, and 17 of 20 were sent for repair based on the risk assessment protocol (Tables 1 and 2). Numerous noncritical defects and at least 1 critical defect were documented by the manufacturer in 13 of 14 available repair reports. According to the manufacturer, critical defects may cause the endoscope to become inoperable or impair clinical performance, potentially resulting in hazardous conditions that could injure patients or health care personnel, whereas noncritical defects may reduce the ease of use or cause range limitations. Six endoscopes were refurbished, whereas the others were repaired. The 3 long-term rental endoscopes in use at final assessment were returned to the manufacturer based on findings, but researchers did not receive repair reports.

Biochemical tests and microbial cultures

Researchers tested every endoscope in use at the final assessment and found a similar proportion of endoscopes in each group

Fig 1. Damaged distal ends of scopes. (A) Cracked lens. (B) Scratched, cloudy lens and eroded covering around light sources. (C) Scratched, scaly lens; eroded covering around light sources; dents near suction-biopsy channel outlet; and brown debris around water channel outlets.

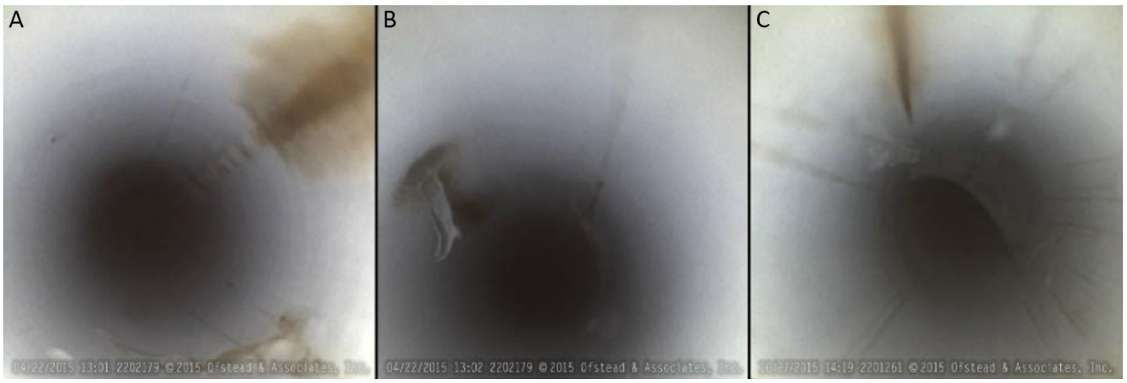

Fig 2. Irregularities observed in colonoscope channels. (A) Scratches and brown discoloration. (B) Filamentous debris and brown discoloration. (C) Scratches and residual fluid.

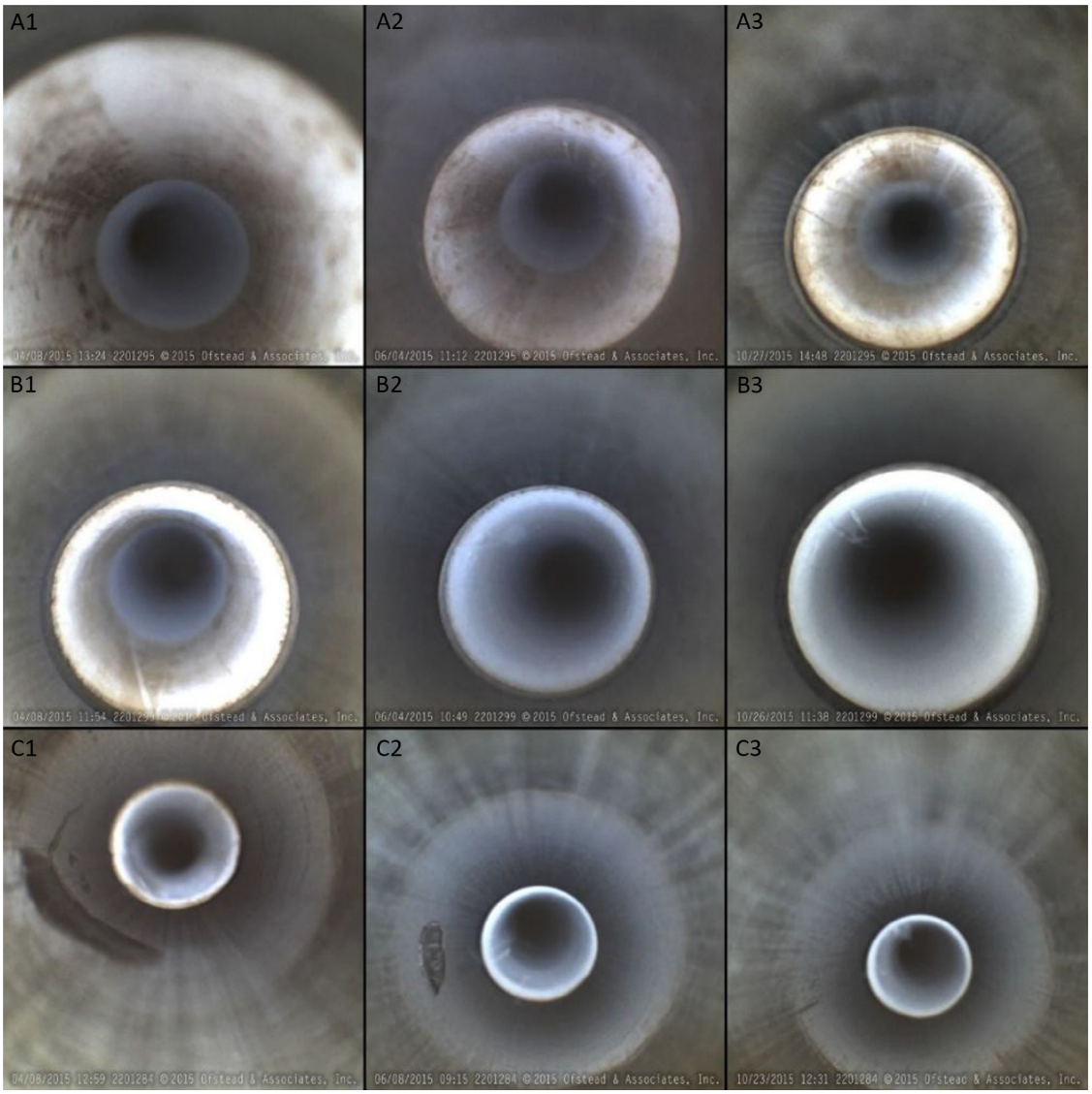

Fig 3. Scratches and discoloration observed in distal ends. (A1) Control group PC-5 at baseline. (A2) Control group PC-5 2-month assessment. (A3) Control group PC-5 at final assessment. (B1) Intervention group PC-6 at baseline. (B2) Intervention group PC-6 at 2 months. (B3) Intervention group PC-6 at final assessment. (C1) Intervention group PC-4 at baseline. (C2) Intervention group PC-4 at 2-month assessment. (C3) Intervention group PC-4 at final assessment.

Table 1
Endoscope visual appearance and repair status at final assessment

Endoscope ID [group]	Visual observations by researchers	Manufacturer reports		
		Critical defects	Noncritical	Comments
Leased endoscopes				
AC-1 [Intervention]	Brown discoloration; scratches; filamentous debris; DE damage; fluid	5	8	Failed leak test; C-cover insulation; lens chipped/cracked; nozzle clogged; A-rubber glue cracked
AC-2 [Control]	Brown discoloration; jagged scratches; filamentous debris; DE damage; fluid;	3	8	Lens chipped/cracked; A-rubber glue cracked; bending section frayed
AC-3 [Intervention]	Rusty discoloration; jagged scratches; filamentous debris; bending section dent; degraded distal sheath; fluid	3*	4	Forceps passage damage; lens chipped/cracked; bending section dent
AC-4 [Control]	Slight discoloration; minor scratches; filamentous debris; fluid	Not sent	Not sent	Not sent
AC-5 [Control]	Slight discoloration; minor scratches; filamentous debris; lopsided channel	Not sent	Not sent	Not sent
AC-6 [Intervention]	Brown discoloration; rough channel surface; scratches; filamentous debris; lopsided channel; fluid	0	8	No critical findings
PC-1 [Control]	Red and brown discoloration; jagged scratches; etched channel surface; filamentous debris; fluid	3*	5	Lens chipped; A-Rubber glue cracked; bending section frayed
PC-2 [Intervention]	Red and brown discoloration; etched surfaces; scratches; worn distal sheath; DE damage; fluid	5	7	Failed leak test; DE plastic cover damage; A-Rubber glue cracked; air water supply cap damage; scope connector loose
PC-3 [Control]	Brown discoloration; deep scratches; worn and chipped distal sheath; insertion tube discoloration; DE damage; brown debris in water channel outlets; fluid	4*	7	C-Cover insulation damage; DE plastic cover cracked; lens chipped/cracked; A-Rubber glue cracked
PC-4 [Intervention]	Brown discoloration; jagged scratches; filamentous debris; lopsided channel; fluid	1	4	A-Rubber glue cracked
PC-5 [Control]	Brown and rusty discoloration; jagged scratches; filamentous debris; insertion tube discoloration; DE dent; fluid	3	5	DE plastic cover damage; lens cracked; A-Rubber glue cracked
PC-6 [Intervention]	Red and brown discoloration; scratches; filamentous debris; lopsided channel; bending section and DE dents; worn distal sheath; fluid	2*	6	Lens chipped/cracked; bending section frayed
Gastro-1 [Control]	Red discoloration; scratches; lopsided channel; DE damage; fluid	1	0	Forceps passage damage
Gastro-2 [Intervention]	Brown discoloration; minor DE scratches; fluid	Not sent	Not sent	Not sent
Gastro-3 [Control]	Brown and orange discoloration; debris; insertion tube buckling; fluid	3*	5	C-Cover insulation damage; lens chipped/cracked; insertion tube chemical damage
Gastro-4 [Intervention]	Brown discoloration; etched channel surface; scratches; worn distal sheath; DE buildup and dent; cracked lens; fluid	3	3	DE plastic cover damage; lens peeling; A-Rubber glue cracked
Gastro-5 [Intervention]	Brown and yellow discoloration; scratches; insertion tube buckling; worn distal sheath; fluid	2*	3	A-Rubber glue cracked; insertion tube chemically damaged/discolored and cut/scratched
Loaned endoscopes				
AC-7 [Control]	Brown discoloration; jagged scratches; filamentous debris; fluid	Sent to manufacturer for repair, status unknown for loaned endoscopes		
PC-7 [Intervention]	N/A	Not in use at final assessment		
PC-8 [Control]	Brown discoloration; jagged scratch; filamentous debris	Sent to manufacturer for repair, status unknown for loaned endoscopes		
Gastro-6 [Control]	N/A	Not in use at final assessment		
Gastro-7 [Intervention]	Brown discoloration; etched channel surface; lopsided channel; DE dent; fluid	Sent to manufacturer for repair, status unknown for loaned endoscopes		

AC, adult colonoscope; *A-Rubber*, bending section cover or bending rubber; *C-cover*, distal tip cover; *DE*, distal end; *Gastro*, esophagogastroduodenoscope; *PC*, pediatric colonoscope.
*Endoscope that was refurbished by the manufacturer.

exceeded the postcleaning benchmarks for ATP (20% control and 30% intervention) and protein (20% control and 20% intervention). Overall, more gastroscopes exceeded the ATP benchmark (67% gastroscope and 7% colonoscope; $P = .014$), but there was no difference in protein levels (17% gastroscope and 21% colonoscope). (Table 2) There were no differences in cleaning effectiveness by endoscope age or use history, and the highest post-HLD microbial colony count was found in 1 of the newer ACs. Although gastroscopes were found to be more highly contaminated than colonoscopes, they were used for fewer procedures than colonoscopes (gastroscopes: mean, 394 uses [range, 384-408 uses]; ACs: mean, 413 uses [range, 388-431 uses, excluding 2 newer colonoscopes with 35 and 40 uses]; and PCs: mean, 513 uses [range, 500-530 uses]) at baseline.

Every endoscope had <10 CFU except 1 intervention AC with 15 CFU (Table 2). Two potential pathogens were found (*Corynebacterium* spp and *Methylobacterium extorquens*). There were no statistically significant differences in the number of endoscopes with positive cultures by study group (control 50% and intervention 70%), assessment period (47% at baseline, 58% at 2 months, and 60% at final assessment), or endoscope type (83% gastroscopes and 50% colonoscopes). Of the 12 endoscopes with growth at the final assessment, samples from 4 endoscopes had no growth until after 48 hours. Samples from 6 endoscopes had growth only on tryptic soy agar, 4 had growth only on blood agar, and 2 had growth on both types of media. The potential pathogens grew only on blood agar and appeared on day 5 or 6.

Positive control samples were highly contaminated (ATP, 4,831 RLU; protein, 29 μg/mL; and microbial cultures, >600 CFU). Negative control samples had low ATP levels (9 RLU), negative protein tests (0 μg/mL), and no microbial growth.

Table 2
Contamination results at final assessment

Endoscope ID	Postcleaning: Protein (μg/mL)	Postcleaning: Adenosine triphosphate* (RLU)	Post high-level disinfection: Cultures (CFU)	Post high-level disinfection: Species identification
AC-1	4	32	0	—
AC-2	11	24	0	—
AC-3	3	16	3	*Staphylococcus* spp; gram-positive rods
AC-4	5	27	1	*Corynebacterium* spp
AC-5	3	13	1	*Bacillus mycoides*
AC-6	3	17	15	*Staphylococcus* spp; *S epidermidis, S hominis, Bacillus atrophaeus*
AC-7†	6	48	0	—
PC-1	4	453	1	Gram-positive rod species
PC-2	6	19	0	—
PC-3	3	57	1	Gram-positive rod species
PC-4	4	11	0	—
PC-5	3	14	0	—
PC-6	4	16	1	*Micrococcus* spp
PC-7†	N/A	N/A	N/A	N/A
PC-8†	4	29	0	—
Gastro-1	5	1353	3	*Micrococcus* spp; *Staphylococcus* spp; gram-positive rod species
Gastro-2	3	1937	1	*Micrococcus* spp
Gastro-3	5	139	0	—
Gastro-4	6	54	2	*Bacillus subtilis*; gram-positive rod species
Gastro-5	3	3138	2	*Micrococcus* spp; *Staphylococcus* spp
Gastro-6†	N/A	N/A	N/A	N/A
Gastro-7†	3	775	1	*Methylobacterium extorquens*

AC, adult colonoscope; *Gastro*, esophagogastroduodenoscope; *N/A*, not in use at final assessment; *PC*, pediatric colonoscope.
*Highest ATP level from biopsy ports or suction biopsy channels for each endoscope.
†Loaner endoscope.

Routine ATP monitoring

Technicians conducted ATP tests after manual cleaning for all intervention endoscopes. Postcleaning benchmarks (<200 RLU) were met during 301 of 304 (99%) colonoscope encounters (mean, 17 RLU and median, 11 RLU), and during 69 of 143 (48%) gastroscope encounters (mean, 571 RLU and median, 214 RLU). In 16 (11%) gastroscope encounters, the ATP levels were still high after double manual cleaning and 2 cycles of cleaning and HLD in the AER.

DISCUSSION

This study was conducted in a setting with fairly new endoscopes, low procedure volumes (mean individual use, <1/day), and verified adherence to reprocessing protocols. Nevertheless, researchers identified numerous visible irregularities, and results of biochemical tests and microbial cultures indicated that reprocessing was not consistently effective, even when more rigorous methods were used for intervention group endoscopes.

Others have reported the persistence of organic material after manual cleaning.[7-10,34] Protein residues may not be removed despite vigorous cleaning,[8,27] and brushing may spread out protein and increase its adherence to surfaces.[35] Our findings suggest the accumulation of biofilm, because we observed an increase in staining and debris over time.

Differences in reprocessing effectiveness were found for gastroscopes versus colonoscopes, although the same reprocessing methods were used. Others have found gastroscopes had more protein residue[27] and higher ATP levels[34,36] than colonoscopes, which could possibly be due to stomach acid and bile exposure during upper gastrointestinal procedures. The implications of our findings are unknown, but contaminated gastroscopes were implicated in an outbreak of extended-spectrum-β-lactamase-producing *Pseudomonas aeruginosa* in France.[22] A recent investigation determined that a gastroscope became contaminated with extended-spectrum-β-lactamase-producing *Klebsiella pneumoniae* from an infected patient and retained the pathogen through 12 reprocessing cycles and use on 9 other patients.[37] More research is needed to determine the reasons for differences in reprocessing effectiveness for gastroscopes versus colonoscopes and to identify more effective ways to reprocess these endoscopes.

In our study, microbial growth was found in samples from 60% of endoscopes. The laboratory incubated samples for 5-7 days at cooler temperatures than those reported by other researchers. Another study found incubation duration affected culture outcomes, with 44.5% of contaminated endoscopes identified after 2 days.[17] If our samples were incubated for only 48 hours, 30% of positives and 2 potential pathogens would have been missed. Others have reported negative cultures when flush-only methods were used for sampling, but identified multidrug-resistant pathogens when brushing was added.[20] Our use of flush-brush-flush sampling may have contributed to finding positive cultures. The lower rates of microbial growth reported by others[12,13] may be due to the protective matrix formed by biofilm,[28] which could have interfered with sampling.

Residual fluid was found in most endoscopes, which suggests that drying methods were not sufficient. The presence of residual fluid could foster the growth of bacteria and fungi. As described previously, further examination detected simethicone in 2 fluid samples.[33] This inert substance is commonly used during endoscopic procedures to reduce foaming and bubbles that impede visualization. Simethicone products contain other substances that may foster microbial growth, and its use may impede reprocessing effectiveness.[38,39]

Although current guidelines recommend more emphasis be placed on visual inspections,[2-4] they do not provide a protocol for conducting visual examinations or interpreting findings. Researchers experienced a substantial learning curve, partially due to the lack of an established lexicon for describing abnormalities and interpreting their relevance. After study initiation, researchers obtained manufacturers' maintenance bulletins and reports from outbreak investigations[21,23,40-42] that described defects and validated researchers' concerns about irregularities. At the final assessment, every endoscope sent to the manufacturer had defects requiring repair or refurbishment. An improvement in our ability to detect and interpret irregularities may have contributed to the increase in documented visual abnormalities from baseline to final assessment, which underscores the need for additional research and guidance on performing visual inspections and interpreting findings.

There were several other study limitations. This was a single-site study with a small sample size, which limited statistical comparisons. The narrower diameter of gastroscope channels and auxiliary water channels precluded full examination, and multiple borescope sizes would have been necessary to examine all channels. We were unable to determine whether improvements in the visual appearance of intervention endoscopes were due to additional cleaning, peracetic acid use, or both. The methods used to conduct microbial cultures did not involve the use of buffers or neutralizers to counteract the presence of any residual cleaning or disinfecting agents that could affect microbial viability. Therefore, our findings may underestimate the quantity of microorganisms present after reprocessing. ATP results for surface swabs of BPs may

have underestimated the true ATP levels because those samples were collected after a sterile swab had been used to sample the port for microbial cultures, which could have removed some of the residual contamination.

This study demonstrated that more rigorous reprocessing practices may not be sufficient to ensure that patient-ready endoscopes are free from residual contamination, particularly when the endoscope has defects that could harbor organic debris and biofilm. Visual inspection and routine monitoring for biochemical markers of residual contamination may be essential to identify suboptimal reprocessing and proactively identify endoscopes in need of repair or refurbishment. Residual fluid found inside endoscopes indicate that current industry standards do not effectively dry endoscopes, which is essential to minimize growth of environmental contaminants and potential pathogens. The association between visual abnormalities, biochemical markers of contamination, microbial growth, and the potential for adverse patient outcomes is not known. Research is needed to establish optimal methods and frequency for assessing endoscopes for visual abnormalities, residual contamination, and microbial growth, as well as a schedule for routine maintenance. At this time, the ultimate goal is for every institution to have documented proof that their endoscopes are in good working order and are not contaminated in ways that put patients at risk.

Acknowledgments

The authors thank Director of Surgical Services Sarah Held, MBA, RN, for providing the researchers with a dedicated procedure room and logistical support during this study. The authors also thank Michelle Alfa, PhD, for providing insights about conducting and interpreting microbial cultures; Catherine Rocco, MSN, RN, CNOR; Evan Doyle, BS; and Gavin Mark, BS; for providing assistance with sample collection and Lisa Mattson, MBA, for handling logistics related to the study. The authors also thank the nursing staff and reprocessing technicians who coordinated the identification of study endoscopes, accommodated our presence in the unit, and re-reprocessed study endoscopes after we examined or sampled them.

SUPPLEMENTARY DATA

Supplementary data related to this article can be found at http://dx.doi.org/10.1016/j.ajic.2016.10.017.

References

1. Beilenhoff U, Neumann CS, Rey JF, Biering H, Blum R, Cimbro M, et al. ESGE-ESGENA guideline: cleaning and disinfection in gastrointestinal endoscopy. Endoscopy 2008;40:939-57.
2. Associate of periOperative Registered Nurses. Guideline for processing flexible endoscopes. Denver (CO): Sterilization and Disinfection; 2016. p. 675-758.
3. Association for the Advancement of Medical Instrumentation, American National Standards Institute. ANSI/AAMI ST91: 2015, Flexible and semi-rigid endoscope processing in health care facilities. Arlington (VA); 2015. p. 1-70.
4. Society of Gastroenterology Nurses and Associates. Standards of infection prevention in reprocessing flexible gastrointestinal endoscopes. Chicago (IL); 2015. p. 1-31.
5. Gastroenterological Society of Australia, Gastroenterological Nurses College of Australia. Infection control in endoscopy. 3rd ed. Victoria, Australia: Digestive Health Foundation; 2011. p. 1-68. Clinical update.
6. Alfa MJ, Fatima I, Olson N. The adenosine triphosphate test is a rapid and reliable audit tool to assess manual cleaning adequacy of flexible endoscope channels. Am J Infect Control 2013;41:249-53.
7. Alfa MJ, Olson N, Degagne P, Simner PJ. Development and validation of rapid use scope test strips to determine the efficacy of manual cleaning for flexible endoscope channels. Am J Infect Control 2012;40:860-5.
8. Fushimi R, Takashina M, Yoshikawa H, Kobayashi H, Okubo T, Nakata S, et al. Comparison of adenosine triphosphate, microbiological load, and residual protein as indicators for assessing the cleanliness of flexible gastrointestinal endoscopes. Am J Infect Control 2013;41:161-4.
9. Ofstead CL, Wetzler HP, Doyle EM, Rocco CK, Visrodia KH, Baron TH, et al. Persistent contamination on colonoscopes and gastroscopes detected by biologic cultures and rapid indicators despite reprocessing performed in accordance with guidelines. Am J Infect Control 2015;43:794-801.
10. Visrodia KH, Ofstead CL, Yellin HL, Wetzler HP, Tosh PK, Baron TH. The use of rapid indicators for the detection of organic residues on clinically used gastrointestinal endoscopes with and without visually apparent debris. Infect Control Hosp Epidemiol 2014;35:987-94.
11. Ofstead CL, Doyle EM, Eiland JE, Amelang MR, Wetzler HP, England DM, et al. Practical toolkit for monitoring endoscope reprocessing effectiveness: identification of viable bacteria on gastroscopes, colonoscopes, and bronchoscopes. Am J Infect Control 2016;44:815-9.
12. Ross AS, Baliga C, Verma P, Duchin J, Gluck M. A quarantine process for the resolution of duodenoscope-associated transmission of multidrug-resistant *Escherichia coli*. Gastrointest Endosc 2015;82:477-83.
13. Brandabur JJ, Leggett JE, Wang L, Bartles RL, Baxter L, Diaz GA, et al. Surveillance of guideline practices for duodenoscope and linear echoendoscope reprocessing in a large health system. Gastrointest Endosc 2016;84:392-9.
14. Rutala WA, Weber DJ, Healthcare Infection Control Practices Advisory Committee. Guideline for disinfection and sterilization in healthcare facilities, 2008. Department of Health & Human Services; 2008. p. 1-158.
15. Alfa MJ, Sepehri S, Olson N, Wald A. Establishing a clinically relevant bioburden benchmark: a quality indicator for adequate reprocessing and storage of flexible gastrointestinal endoscopes. Am J Infect Control 2012;40:233-6.
16. Buss AJ, Been MH, Borgers RP, Stokroos I, Melchers WJ, Peters FT, et al. Endoscope disinfection and its pitfalls—requirement for retrograde surveillance cultures. Endoscopy 2008;40:327-32.
17. Saliou P, Le Bars H, Payan C, Narbonne V, Cholet F, Jézéquel J, et al. Measures to improve microbial quality surveillance of gastrointestinal endoscopes. Endoscopy 2016;48:704-10.
18. Kovaleva J, Peters FT, van der Mei HC, Degener JE. Transmission of infection by flexible gastrointestinal endoscopy and bronchoscopy. Clin Microbiol Rev 2013;26:231-54.
19. Epstein L, Hunter JC, Arwady MA, Tsai V, Stein L, Gribogiannis M, et al. New Delhi metallo-beta-lactamase-producing carbapenem-resistant *Escherichia coli* associated with exposure to duodenoscopes. JAMA 2014;312:1447-55.
20. Aumeran C, Poincloux L, Souweine B, Robin F, Laurichesse H, Baud O, et al. Multidrug-resistant *Klebsiella pneumoniae* outbreak after endoscopic retrograde cholangiopancreatography. Endoscopy 2010;42:895-9.
21. Verfaillie CJ, Bruno MJ, Voor in 't Holt AF, Buijs JG, Poley JW, Loeve AJ, et al. Withdrawal of a novel-design duodenoscope ends outbreak of a VIM-2-producing *Pseudomonas aeruginosa*. Endoscopy 2015;47:493-502.
22. Bajolet O, Ciocan D, Vallet C, de Champs C, Vernet-Garnier V, Guillard T, et al. Gastroscopy-associated transmission of extended-spectrum beta-lactamase-producing *Pseudomonas aeruginosa*. J Hosp Infect 2013;83:341-3.
23. Food and Drug Administration. MAUDE adverse event report: Olympus Medical Systems Corporation Olympus Evis Exera colonovideoscope colonoscope. 2009. MDR 1579940.
24. Food and Drug Administration. Infections associated with reprocessed flexible bronchoscopes: FDA safety communication. September 17, 2015.
25. Chang CL, Su LH, Lu CM, Tai FT, Huang YC, Chang KK. Outbreak of ertapenem-resistant Enterobacter cloacae urinary tract infections due to a contaminated ureteroscope. J Hosp Infect 2013;85:118-24.
26. Wendelboe AM, Baumbach J, Blossom DB, Frank P, Srinivasan A, Sewell CM. Outbreak of cystoscopy related infections with *Pseudomonas aeruginosa*: New Mexico, 2007. J Urol 2008;180:588-92.
27. Herve RC, Keevil CW. Persistent residual contamination in endoscope channels; a fluorescence epimicroscopy study. Endoscopy 2016;48:609-16.
28. Neves MS, Gomes da Silva M, Ventura GM, Cortes PB, Duarte RS, de Souza HS. Effectiveness of current disinfection procedures against biofilm on contaminated GI endoscopes. Gastrointest Endosc 2016;83:944-53.
29. Kovaleva J, Meessen NE, Peters FT, Been MH, Arends JP, Borgers RP, et al. Is bacteriologic surveillance in endoscope reprocessing stringent enough? Endoscopy 2009;41:913-6.
30. Alfa MJ, Fatima I, Olson N. Validation of adenosine triphosphate to audit manual cleaning of flexible endoscope channels. Am J Infect Control 2013; 41:245-8.
31. Centers for Disease Control and Prevention. Interim protocol for healthcare facilities regarding surveillance for bacterial contamination of duodenoscopes after reprocessing. Atlanta (GA): Department of Health & Human Services; 2015. p. 1-5.
32. Ofstead CL, Wetzler HP, Eiland JE, Heymann OL, Held SB, Shaw MJ. Assessing residual contamination and damage inside flexible endoscopes over time. Am J Infect Control 2016;doi:10.1016/j.ajic.2016.06.029; [Epub 7 Sep 2016].
33. Ofstead CL, Wetzler HP, Johnson EA, Heymann OL, Maust TJ, Shaw MJ. Simethicone residue remains inside gastrointestinal endoscopes despite reprocessing. Am J Infect Control 2016;doi:10.1016/j.ajic.2016.05.016; [Epub 3 Aug 2016].
34. Bommarito M, Thornhill G, Morse D. A multi-site field study evaluating the effectiveness of manual cleaning of flexible endoscopes with an ATP detection system. Am J Infect Control 2013;41:S24.

35. Herve R, Keevil CW. Current limitations about the cleaning of luminal endoscopes. J Hosp Infect 2013;83:22-9.
36. Alfa MJ, Olson N, Murray BL. Comparison of clinically relevant benchmarks and channel sampling methods used to assess manual cleaning compliance for flexible gastrointestinal endoscopes. Am J Infect Control 2014;42:e1-5.
37. England D, Houseman J, Horn L, Mascotti K, Kline S. Documented transmission of extended-spectrum beta-lactamase-producing Klebsiella pneumoniae from patient to gastroscope. Infect Control Hosp Epidemiol 2016;37:493-4.
38. Catalone BJ. Simethicone. Letter to health care practitioner. Olympus; June 9, 2009.
39. PENTAX Medical Company. Instructions for use: Pentax video GI scopes 90i series 90K series. Japan; 2014.
40. Vos MC. The role of the ERCP duodenoscope in the outbreak by VIM positive P. aeruginosa at the Erasmus MC. FDA gastroenterology-urology devices panel. Washington DC; 2015.
41. Wendorf KA, Kay M, Baliga C, Weissman SJ, Gluck M, Verma P, et al. Endoscopic retrograde cholangiopancreatography-associated AmpC Escherichia coli outbreak. Infect Control Hosp Epidemiol 2015;36:634-42.
42. Food and Drug Administration. MAUDE adverse event report: Olympus Medical Systems Corporation Olympus Evis Exera II duodenovideoscope duodenoscope. 2016. MDR 5456009.